

Figure. 1. Pathological consultation graphic report

Pathological consultation graphic report

Consultation number: H202001626

Name: Gender: female Age: 25 years old

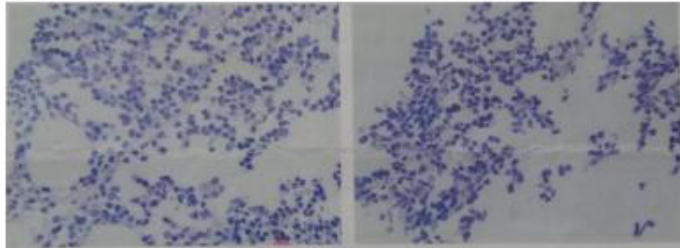
ID number: 8002584154 Department: gynecological clinic The doctor who ordered the test: Date of application: 2020-08-07

Clinical diagnosis: Embryonal rhabdomyosarcoma of the left vulva after 4 cycles of chemotherapy Date of report: 2020-08-10

Material tested: One specimen of HE and Eight white specimens Original pathology number: 2003565

Seen microscopically:

Automatic rapid immunohistochemical results: CK (-), Desmin (+), Myogenin (+), MyoD1 (+), CD45 (+), WT-1 (-), CD56(+).



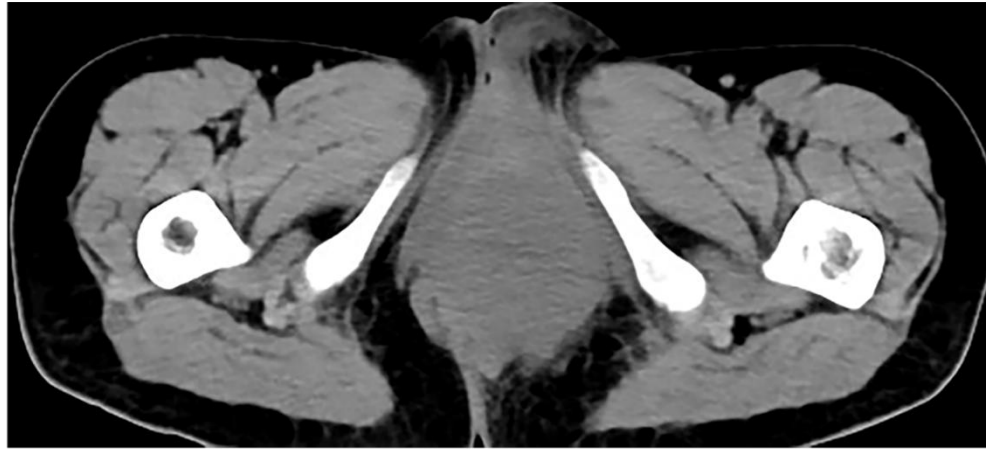Pathological consultation opinion:

(Puncture of the left vulvar mass) Small cell malignancy, embryonal rhabdomyosarcoma was considered.

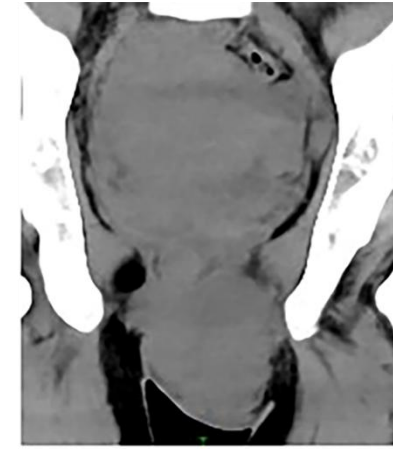Reporting doctor:

Reviewing doctor:

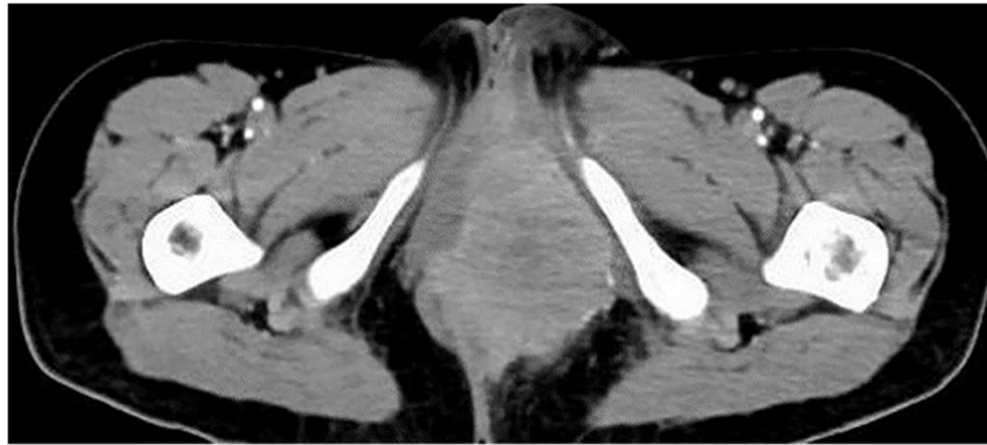Note: Pathological consultation graphic report translated version



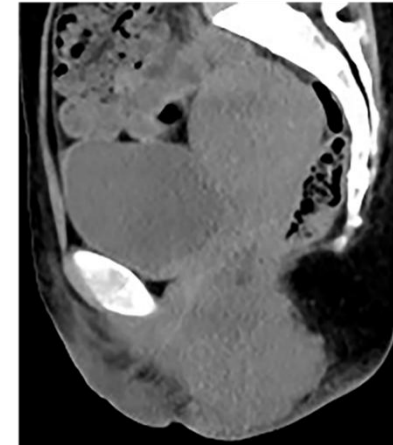
A



C



B



D

Figure. 2. Axial (A), coronal (C) and sagittal unenhanced CT (D), and axial contrast-enhanced CT (B) before iliac after induced abortion.